

Robot-assisted Resection of a Retroperitoneal Schwannoma: Case report and review of the literature

Ressecção Robô – Assistida de Schwannoma Retroperitoneal: Relato de Caso e Revisão da Literatura

RICARDO ZUGAIB ABDALLA^{1,2,3,4}; RODRIGO BISCUOLA GARCIA^{1,2,3,4};
RAFAEL IZAR DOMINGUES DA COSTA^{3,4}

Hospital Sírio-Libanês, São Paulo, SP, Brazil.

¹. Membro titular da SOBRACIL; ². Membro titular do Colégio Brasileiro de Cirurgia; ³. Médico do Hospital Sírio-Libanês, São Paulo; ⁴. Médico do Hospital São José, São Paulo.

ABSTRACT

BACKGROUND - Schwannomas are tumors that originate from Schwann cells; they form solitary masses in peripheral nerve sheath. CASE REPORT - A 36 year old, male patient, with a solid mass in area of the left adrenal gland identified upon routine exam. He underwent robot-assisted resection of the retroperitoneal mass; the anatomical-pathological analysis revealed a Schwannoma. CONCLUSION - The robot-assisted approach has been shown to be a safe option in abdominal surgeries, offering the patient the opportunity of a fast recovery and earlier return to normal activities.

Key words: Neuroma. Retroperitoneal neoplasms. Robotics.

Braz. J. Video-Sur, 2013, v. 6, n. 2: 083-085

Accepted after revision: february, 13, 2013.

INTRODUCTION

Schwannomas are tumors originating from Schwann cells, present in the peripheral nerve sheath. They occur as encapsulated solitary masses, usually involving cranial nerves. This type of tumor rarely recurs after local resection.¹

About 0.5% of Schwannomas occur in the retroperitoneum. They tend to be insidious and slow growing and thus are often quite large when discovered, and even then rarely symptomatic.² They may be an incidental finding on a routine physical examination or found when complaints of adjacent organ are investigated.

A Schwannoma may occur sporadically or in association with Neurofibromatosis type II (von Recklinghausen's Disease). In virtually all cases, its presence is due to an alteration in or to the absence of the NF2 gene, which, in turn, is involved in the growth of Schwann cells.³

The diagnosis of Schwannoma is histopathological, by means of immunohistochemistry. Neurofibromatosis can often be excluded due to the absence of clinical criteria; thus genetic analysis is

not indicated in most suspected cases. Complete resection of the lesion together with its capsule affords a good prognosis.⁴

CASE REPORT

The patient is a married 36 year old male, born and raised in São Paulo, who underwent an abdominal ultrasound that showed a slightly hypoechoic expansive and heterogeneous solid lesion, measuring 9.3 x 7.4 x 8.2 cm, with central cystic areas, located close to the left adrenal, displacing the left kidney inferiorly and the spleen laterally.

Prompted by the findings of the abdominal ultrasound, magnetic resonance imaging (MRI) of the abdomen with contrast was obtained. A large solid mass, measuring 9.8 X 9.0 X 8.5 cm, with areas of necrosis was identified close to the left adrenal. The MRI study showed subtle, gradual uptake of contrast by the tumor, and that it displaced the pancreatic tail anteriorly and the spleen laterally.

Given the suspicion of left adrenal tumor raised by the imaging studies, plasma metanephrine concentrations and 24-hour urinary collection for

catecholamines, vanillyl mandelic acid (VMA) and metanephrines were ordered. All values were normal.

Due to the size of the lesion and the possibility that it arose from the left adrenal gland, robot-assisted videosurgery was recommended. The patient was placed in a supine position. Five incisions were made: the first for the 12mm optic of the robot in the umbilical scar, and three 8 mm incisions for the robotic arms in the right hypochondrium, in the left hypochondrium and in the right para-umbilical region. Finally, we made a 12 mm incision to the left of the umbilicus, for the assistant, who remains beside the patient, while the surgeon sits at the robot console.

During the initial inspection, a well-defined, encapsulated mass was observed in the region posterior to the splenic flexure of the colon, between the spleen and tail of the pancreas. No other intra-abdominal lesions were seen. The left parieto-colic gutter was opened, and the splenic flexure was pulled toward the midline (Figure 1). Given the rounded appearance of the tumor, we opted strategically for cleavage along a proximal-distal plane, and rolling it cranially (Figure 2). Because of the technical characteristics of the method, we were able to expose the supra-pancreatic plane, and isolate and cauterize the vessels of the region safely and effectively. (Figure 3).

Even with the tumor essentially freed from the more vascularized tissue of the splenic hilum and the cranial border of the pancreas, its removal was challenging because of its weight.

So, a small midline supra-umbilical laparotomy was performed; linear stapling of the remaining adhesions of the tumor was performed to facilitate the removal of the surgical specimen, which measured 14 cm in its greatest dimension.

The result of the histological examination was Schwannoma with diffuse immunoreexpression of S-100 protein, weakly positive for vimentin, and a Ki-67 proliferative index of 5%.

The patient was discharged on the second postoperative day, with good oral intake, adequate pain control with oral analgesics, and no procedure-related morbidity.

DISCUSSION

Because it is an extremely rare tumor, the diagnosis of a retroperitoneal Schwannoma by imaging is difficult. The inclination to leave an unknown tu-

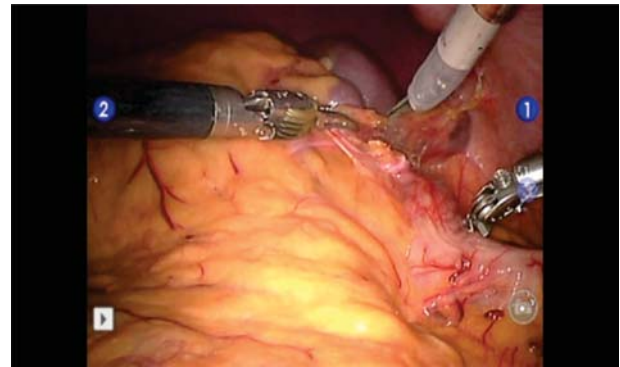


Figure 1 - Opening of the retroperitoneal cavity to expose the tumor.

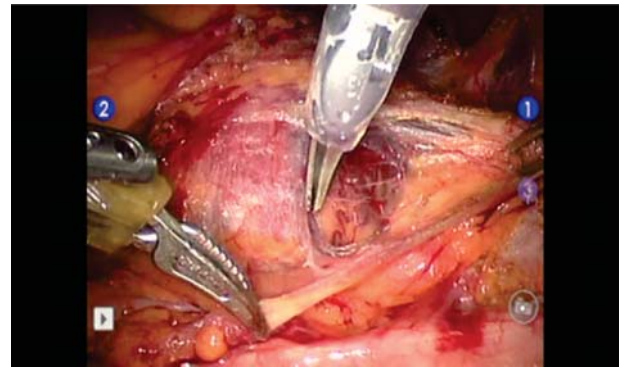


Figure 2 - Initiating the tumor dissection by separating the visceral fat.

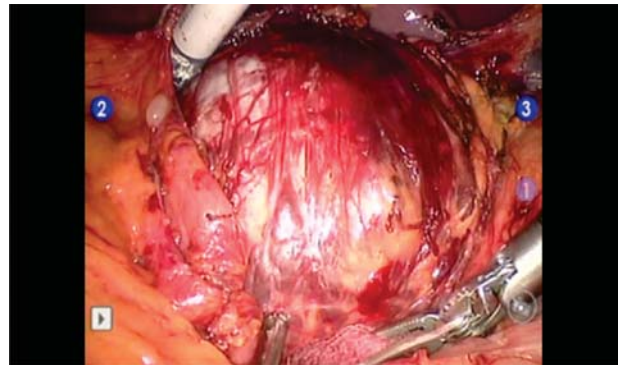


Figure 3 - With the dissection completed, it is possible to see that the tumor is isolated from the neighboring organs, with well defined margins.

mor intact usually supersedes any desire to obtain an image-guided biopsy. Thus, complete surgical excision of the tumor ends up being the preferred option.⁵ In only one case reported in the literature was the preoperative diagnosis established by endoscopic ultrasound-guided fine-needle biopsy.⁶

In this case, surgical treatment was prompted by the belief that the mass was an adrenal tumor, a

situation in which the resection was indicated due to the tumor's size. Also weighing on the decision to use the robot was the possibility of performing a resection close to the large vessels with the advantage of steadiness of the robotic arm, a view validated to a certain extent during the procedure.

Minimally invasive surgery is becoming more popular in the treatment of retroperitoneal tumors, with reports of laparoscopic resection of Schwannomas in this region.^{7,8,9} There is no report in the literature of a retroperitoneal Schwannomas removed by robot-assisted surgery; we believe this is the first such case report.

We found the robot especially useful in the dissection between the tumor and the adjacent retroperitoneal structures. It affords the surgeon a view in three dimensions (depth sensation) and the image definition is far superior to that of laparoscopy. Furthermore, the stability of the robotic arms was

essential in handling a bulky and heavy tumor, enabling the resection through a minimally invasive approach.

CONCLUSION

The robotic approach has been gaining ground as a safe and effective technique in abdominal surgery. It has applicability in oncologic surgery because it 1) facilitates dissection in situations of close approximation of the tissues, 2) preserves tissues free of tumor, and 3) affords the surgeon greater freedom of movement. The panoramic and three dimensional views and superior visual quality, combined with the minimally invasive approach, benefit the procedure and confer greater confidence in the surgical technique. The patient enjoys a better and faster recovery compared to traditional methods, and the surgeon enjoys better ergonomics, comfort, and ease while operating.

RESUMO

INTRODUÇÃO - Os schwannomas são tumores que se originam das células de Schwann, formando lesões solitárias na bainha dos nervos periféricos. **RELATO DO CASO** - Paciente de 36 anos, do sexo masculino, com quadro de lesão sólida na topografia de glândula adrenal esquerda, identificada em exame de rotina. Foi submetido a ressecção por via robô-assistida de massa em retroperitônio, que ao anátomo-patológico mostrou tratar-se de Schwannoma. **CONCLUSÃO** - A via robô-assistida mostrou ser opção segura na realização de cirurgias abdominais, trazendo ao paciente oportunidade de recuperação rápida e retorno mais cedo às atividades.

Descritores: Neuroma. Neoplasias retroperitoneais. Robótica.

REFERENCES

1. Karakousis C. Sarcomas de nervos periféricos. In: Lopes A. Sarcomas de partes moles. Rio de Janeiro: Medsi; 1999. P. 503 - 510.
2. Dawley B. A retroperitoneal femoral nerve schwannoma as a cause of chronic pelvic pain. J Minim Invasive Gynecol. 2008;15(4):491-3.
3. Fass G, Hossey D, Nyst M, Smets D, Saligheh EN, Duttman R, Claes K, da Costa PM. Benign retroperitoneal schwannoma presenting as colitis: a case report. World J Gastroenterol. 2007; 13(41):5521-4.
4. Nah YW, Suh JH, Choi DH, Ko BK, Nam CW, Kim GY, Im YC, Cho HR. Benign retroperitoneal schwannoma: surgical consideration. Hepatogastroenterology 2005; 52(66):1681-4.
5. Mingione A, Cirillo C, Martucci N, Mingione S. Benign retroperitoneal schwannoma: a case report and review of the literature. Chir Ital. 2009; 61(1):107-12.
6. Li S, Ai SZ, Owens C, Kulesza P. Intrapaneatic schwannoma diagnosed by endoscopic ultrasound-guided fine-needle aspiration cytology. Diagn Cytopathol. 2009; 37(2):132-5.
7. Maresma C, Raventós CX, Celma A, Vallejo JB, De los Santos AO, Robles JM. Benign retroperitoneal schwannoma, laparoscopic resection. Actas Urol Esp. 2008; 32(4):455-7.
8. Kang CM, Kim DH, Seok JY, Lee WJ. Laparoscopic resection of retroperitoneal benign schwannoma. J Laparoendosc Adv Surg Tech 2008; 18(3):411-6.
9. Pinto D, Kaidar-Person O, Cho M, Zundel N, Szomstein S, Rosenthal RJ. Laparoscopic resection of a retroperitoneal degenerative schwannoma: a case report and review of the literature. Surg Laparosc Endosc Percutan Tech. 2008; 18(1):121-3.

Corresponding author:

RODRIGO BISCUOLA GARCIA

Rua Barata Ribeiro 237 Cj. 111

Bela Vista, São Paulo 01308-000 Brazil

Tel.: 55 11 3255-1093

E-mail: drgarciairurgia@gmail.com