

## Endoscopic Treatment of Biliary Fistula Post-Laparoscopic Cholecystectomy - Case Report

PAULA PERUZZI ELIA<sup>1</sup>; JOSÉ MAURO TEIXEIRA<sup>2</sup>; GUTEMBERG CORREIA DA SILVA<sup>3</sup>; GREGÓRIO FELDMAN<sup>4</sup>; FERNANDO PERES<sup>5</sup>; MIGUEL DE MIRANDA GONÇALVES<sup>6</sup>; ÁLVARO AUGUSTO GUIMARÃES FREIRE<sup>7</sup>

<sup>1</sup> Master of science in Gastroenterology at Universidade Federal do Rio de Janeiro, Physician in charge of the Pediatric Gastrointestinal Endoscopy Service at Instituto Fernandes Figueira – FIOCRUZ; <sup>2</sup> Physician in charge for Endoscopic Retrograde Cholangiopancreatography at GASTROENDO; <sup>3</sup> Master of Science in Gastroenterology at Universidade Federal do Rio de Janeiro, Member of the Brazilian Society for Gastrointestinal Endoscopy; <sup>4</sup> Member of the American Society for Gastrointestinal Endoscopy (ASGE), Member of the Brazilian Society for Gastrointestinal Endoscopy; <sup>5</sup> Physician at the Gastrointestinal Endoscopy Service at the Hospital dos Servidores do Estado e do Hospital Geral de Nova Iguaçu; <sup>6</sup> Surgeon at Hospital Panamericano; <sup>7</sup> Physician in charge for Endoscopic Retrograde Cholangiopancreatography at GASTROENDO.

### ABSTRACT

**Objective:** To report a case of biliary fistula after a non responsive surgical surgical treatment, which was successfully treated endoscopically by ERCP with a biliary stent. **Case Report:** 48 year-old female patient was submitted to a laparoscopic cholecystectomy due to gallstones, after surgery the patient developed jaundice and choleperitoneum. She was submitted to a conventional open abdominal surgery twice without success in closing the biliary fistula. An ERCP was performed with the insertion of a biliary endoprosthesis which permitted the definitive treatment of the lesion. **Discussion:** Injuries of the biliary tract can occur as a complication of laparoscopic cholecystectomy. New endoscopic approaches allow less invasive treatments of those injuries; therefore, postponing or even avoiding surgical treatment.

**Key words:** Cholangiopancreatography; Biliary Fistula; Laparoscopy.

Braz. J. Video-Sur, 2008, v. 1, n. 3: 133-135

Accepted after revision: June, 16, 2008.

Laparoscopic cholecystectomy (LC) was pioneered in France and introduced in the United States in 1988<sup>1,2</sup>. This procedure has some advantages associated to open cholecystectomy, such as shorter hospital stay, decreased postoperative morbidity, better statistic results and faster return to normal activities. However, in the literature several studies report <sup>2,3,4,5</sup> that complications to the biliary tract are more common with LC when compared to open cholecystectomy. Several authors<sup>1,3</sup> impute it to a “learning curve phenomenon”, which frequently occurs after the introduction of any new procedure or technology, thus this is still a controversial data. Some studies have demonstrated that biliary injury after LC remains a persistent problem, which are not declining over the years<sup>6,7</sup>.

Postoperative biliary injuries have always required a complex treatment; however, in the last decade endoscopic and radiologic approaches technology development has permitted a less invasive approach to them, with similar or reduced morbidity rates at surgical treatment<sup>8</sup>.

Biliary tract injuries are consequences of direct injuries (direct trauma by manipulation) and indirect injuries such as extensive dissections that leads to microvascular ischemia or intensive inflammatory process due to the use of monopolar eletrocautery<sup>3,8</sup>. Discontinuity of the bile duct is a serious complication, and it may be diagnosed during surgery or more commonly at the postoperative. Digestive endoscopy has an important role in the treatment of biliary fistulas, especially the ones with low and medium output, short extension and located in the middle and distal portion of the extrahepatic biliary tract<sup>3</sup>. The endoscopic procedure consists of extensive papillotomy to obtain better biliary drainage and to pass a plastic prosthesis, in order to direct the flow distally through capillarity and reduce the fistula output.

### CASE REPORT

S.B.A., a 48-year-old female patient was submitted to laparoscopic surgery for cholelithiasis and

four days after the surgery started to complain of abdominal pain. Two weeks after the surgery the patient returned to the emergency service with abdominal distension, jaundice, nausea and vomit. A CT scan was performed which revealed a great amount of free liquid into the abdominal cavity. The patient was referred to surgery where a voluminous choleperitoneum and small discontinuity of common hepatic duct was revealed during an exploratory laparotomy. Surgical treatment with choledochostomy, insertion of Kehr tube and peritoneal cleansing was performed twice in a 15-day interval period; however, it was not successful and the patient remained with abdominal pain and there were formation of new intra-abdominal fluid collection.

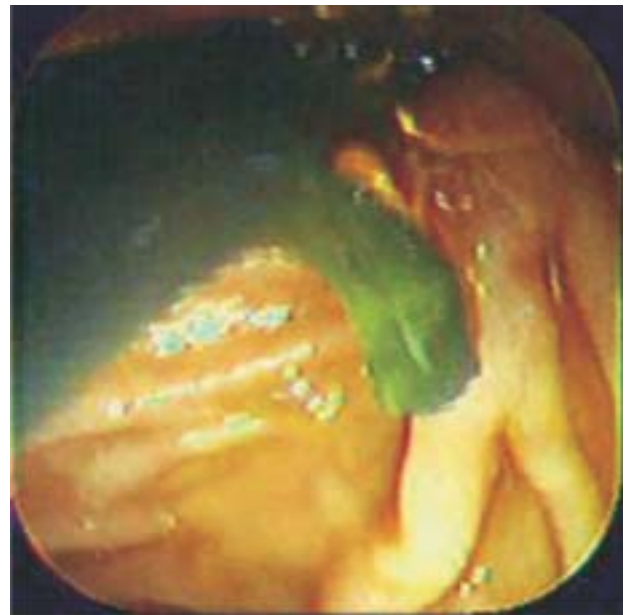
Endoscopic retrograde cholangiopancreatography (ERCP) was performed which revealed the presence of bilioperitoneal fistula, thus it was performed the dilatation of the track and a 7 FR X 10 cm endoprosthesis was inserted (Figure 1), and a good biliary drainage was accomplished. The patient persisted with residual choleperitoneum, so on the seventh day after the endoscopic procedure a computed tomography guidewire puncture of the peritoneal cavity was performed with the placement of a pig tail stent for its daily cleansing. After 20 days of parenteral nutrition and use of somatostatin, there was total regression of the biliary fistula. For 6 months, the patient has been followed-up in the ambulatory, and there was no symptom recurrence, then a new ERCP was performed in order to exchange the plastic prosthesis to a 10 FR X 10 cm prosthesis. The examination revealed only a small scar stenosis of the proximal portion of the choledoco (Figure 2).

## DISCUSSION

Postoperative biliary fistulas are defined as bile leaks through iatrogenic biliary injury. It may occur as a laparoscopic cholecystectomy complication, and they manifest through abdominal pain, distension and fever associated or not to other sepsis signs. A leaked bile may lead to a choleperitoneum, as well as it may be blocked forming a bilioma or may drain spontaneously through an incision<sup>3</sup>. The symptoms may be nonspecific, and if the surgeon does not observe it with care, the diagnosis may occur lately after the development of the systemic manifestations<sup>3,8</sup> or sepsis.

The ERCP has a great value for the iatrogenic biliary injuries diagnosis, as it confirms its diagnosis, evaluating the location and the presence of associated injuries, in addition to promoting a therapeutic approach<sup>8</sup>.

In this case report, we presented a patient with a laparoscopic surgery complication in whom surgical treatment had been performed twice, without successful closure of the biliary fistula. During the endoscopic procedure an extensive papillotomy and dilatation of the track was performed, in order to insert a plastic prosthesis. This therapeutic intervention reduced the biliary pressure and directed the flow distally, through capillarity which reduced the biliary



**Figure 1-** Endoscopic aspect of the duodenal papilla with biliary prosthesis.



**Figure 2-** Radiological aspect of the biliary path after surgery.

output. The ERCP allowed a precise diagnosis of the injury as well as its definitive treatment with low morbidity and mortality.

## CONCLUSION

ERCP has permitted the treatment of different pathologies of the biliary tract, in special the choledocholithiasis, which should be considered a gold standard approach for surgeons in the diagnosis and treatment of biliary tract surgical complications.

## REFERENCES

1. Khan MH, Howard TJ, Fogel EL, Sherman S, McHenry L, Watkins JL et al. Frequency of biliary complications after laparoscopic cholecystectomy detected by ERCP: experience at a large tertiary referral center. *Gastrointest Endosc* 2007; 65(2): 247-52.
2. NIH consensus conference statement on gallstones and laparoscopic cholecystectomy. *Am J Surg* 1993; 165: 390-8.
3. Sakai P, Ishioka S, Maluf Filho F. Tratado de endoscopia digestiva diagnóstica e terapêutica. Vias biliares e pâncreas. In: Matuguma SE, Melo J M, Artifon ELA e Sakai P. Estenoses e fístulas biliares benignas pós-cirúrgicas e pós-traumáticas. 1<sup>o</sup>ed. São Paulo: Atheneu; 2005. p. 139-46.
4. Strasberg SM, Hertl M, Soper NJ. An analysis of the problem of biliary injury during laparoscopic cholecystectomy. *J Am Coll Surg* 1995; 180:101-25.
5. Mirza DF, Narsimhan KL, Ferraazneto BH et al. Biliary injury following laparoscopic cholecystectomy: referral pattern and management. *Br J Surg* 1997; 84: 786-90.
6. Windsor JA, Pong J. Laparoscopic biliary injury: more than a learning curve problem. *Aust N Z J Surg* 1998; 68: 186-9.
7. Sivak MV. Gastroenterologic Endoscopy. In: Huibregtse k, Meenan J, Rauws EAJ, Parasher VK. Diagnosis and management of non neoplastic biliary obstruction, biliary leakage, and disorders of the liver affecting the bile ducts. 2<sup>nd</sup> ed. Cleveland: W.B. Saunders Company; XX 976-88.
8. Ferrari AP, Paulo GA, Thuler FP. Endoscopia Gastrointestinal Terapêutica. In: SOBED. Terapêutica endoscópica nas complicações cirúrgicas e pós-transplantes hepáticos. 1<sup>o</sup> ed. São Paulo: Tecmedd. P.1463-76.

### Correspondence Address:

PAULA PERUZZI ELIA  
Rua Visconde de Pirajá 228 apto 404  
Ipanema - Rio de Janeiro CEP 22410-000  
FAX: (21) 3507-6524 / Phone: 7815-7741 / 9572-9191  
paulaelia@iff.fiocruz.br