

# How do I treat Ovarian Dermoid Cyst by Laparoscopy?

## Como eu Trato Cisto Dermóide Ovariano por Laparoscopia?

MONICA TESSMANN ZOMER<sup>1</sup>; REITAN RIBEIRO<sup>2</sup>; ANIBAL WOOD BRANCO<sup>3</sup>;  
ALCIDES JOSÉ BRANCO FILHO<sup>4</sup>; WILLIAM KONDO<sup>5</sup>

*Sugisawa Medical & Hospital Center. Vita Batel Hospital. Red Cross Hospital.*

*<sup>1</sup> Gynecologist of the Sugisawa Medical & Hospital Center, Vita Batel Hospital, and Red Cross Hospital, Curitiba, Paraná; <sup>2</sup> Oncologist of Erasto Gaertner Hospital and of Vita Batel Hospital, Curitiba, Paraná; <sup>3</sup> Urologist of Vita Batel Hospital and the Red Cross Hospital. Curitiba, Paraná; <sup>4</sup> General Surgeon of Vita Batel Hospital and the Red Cross Hospital. Curitiba, Paraná; <sup>5</sup> General Surgeon and Gynecologist of the Sugisawa Medical & Hospital Center, of Vita Batel Hospital, and the Red Cross Hospital. Curitiba, Paraná.*

---

### ABSTRACT

Laparoscopy is the gold standard for the management of benign ovarian cysts. Standardization of the surgical technique and the application of some tactics during the laparoscopic treatment of ovarian dermoid cysts increase the safety of the procedure and decrease the procedure-related morbidity. In this manuscript the authors describe the technical details of the laparoscopic management of ovarian dermoid cysts.

**Key words:** Benign cystic teratoma, dermoid cyst, laparoscopy, spillage.

**Bras. J. Video-Sur, 2011, v. 4, n. 2: 084-090**

*Accepted after revision: september, 13, 2010.*

### INTRODUCTION

The dermoid cyst, also called benign cystic teratoma is a benign ovarian tumor common in women of reproductive age.<sup>1</sup> It corresponds to 20% to 25% of ovarian tumors and occurs bilaterally in 10 to 15% of cases.<sup>2</sup> Most dermoid cysts are asymptomatic and diagnosis is usually incidental during a routine pelvic exam or pelvic ultrasound.<sup>3</sup> The prevalence of malignant transformation has been reported in 1% to 3%.<sup>2,4</sup>

Surgical treatment aims to avoid potential complications such as torsion, spontaneous rupture (with subsequent chemical peritonitis), infection, malignancy, and possible loss of ovarian parenchyma due to progressive growth of lesion.<sup>5</sup> Traditionally, the treatment of dermoid cyst was ovarian cystectomy or oophorectomy by laparotomy, taking the utmost care to avoid contamination of the abdominal cavity with the intracystic content.<sup>3</sup> The main concern of the application of laparoscopy in the management of dermoid cyst is still the risk of leakage of intracystic contents into the abdominal cavity (spillage) in case of accidental rupture of the cyst, which can in theory produce a chemical peritonitis.<sup>5-7</sup> Although this risk

appears to be low,<sup>1</sup> it should not be underestimated and some safety measures should be applied when dealing with dermoid cysts by laparoscopy.<sup>5</sup> In this article we describe the technical details of laparoscopic management of dermoid cysts.

### SURGICAL TECHNIQUE / PATIENT POSITIONING

The patient is placed in the lithotomy position, with arms alongside the body and thighs abducted, with a slight flexion. The bladder is catheterized with a 12 or 14 French Foley catheter.

### UTERINE CANNULATION

The uterine cannulation can be performed with a curette. The vaginal speculum is placed. The cervix is identified and the anterior lip, clamped with the aid of a Pozzi clamp. A curette is inserted through the cervix to the uterine fundus and secured to a Pozzi forceps with a sterile micropore. In this way, the uterus can be mobilized by the second assistant, facilitating surgical exposure of the pelvic organs.

## POSITIONING OF THE TROCARS/ PORTS

The Veres needle is positioned in the left hypochondrium point (Palmer's point), in the midclavicular line on the left, about 2 cm below the left costal margin.

The positioning of the trocars is standardized for almost all gynecologic laparoscopies, varying only in cases of large pelvic ovarian or uterine mass.

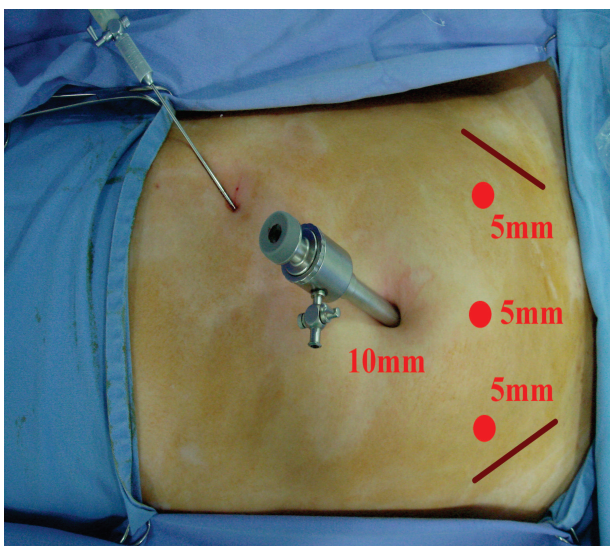
The 10mm trocar is positioned in the umbilical region and three 5mm trocars are positioned as follows: the first 2 cm medial to the left anterior superior iliac spine, the second in the midline, 8 to 10 cm below the umbilical puncture, and the third 2 cm medial to the right anterior superior iliac spine (Figure 1).

## APPROACHING/ADDRESSING THE DERMOID CYST

The importance of using an endobag to protect the pelvic cavity from the contents of the dermoid cyst in the event of its accidental rupture has been described in the literature.<sup>5,8,9</sup> The endobag is inserted into the abdomen through the 10mm umbilical port/trocar and positioned below the ovary to be treated. From this moment, some technical variations can be applied to the procedure:

### Cystectomy without puncture

The ovarian parenchyma is coagulated in the contralateral portion of the pelvic infundibulum and



**Figure 1** - Classic Position of the trocars/ports in gynecologic laparoscopy.

sectioned superficially until one is able to identify the dermoid cyst wall. The sectioning is widened/extended to about 50% of the circumference of the ovarian parenchyma. Then the ovarian parenchyma is separated from the cyst wall using traction and countertraction. In some cases this separation can be achieved by means of grabbing each of the cut edges of the ovarian parenchyma and compressing them against the pelvic wall. In this way, the cyst is enucleated within the ovarian parenchyma. Usually some bleeding will occur in the proximity of the pelvic infundibulum, where bipolar coagulation is recommended before finalizing the freeing of the cyst from the ovarian parenchyma (Figure 2). The enucleated cyst is punctured inside the endobag and its contents are aspirated (Figure 3).

### Cystectomy after puncture

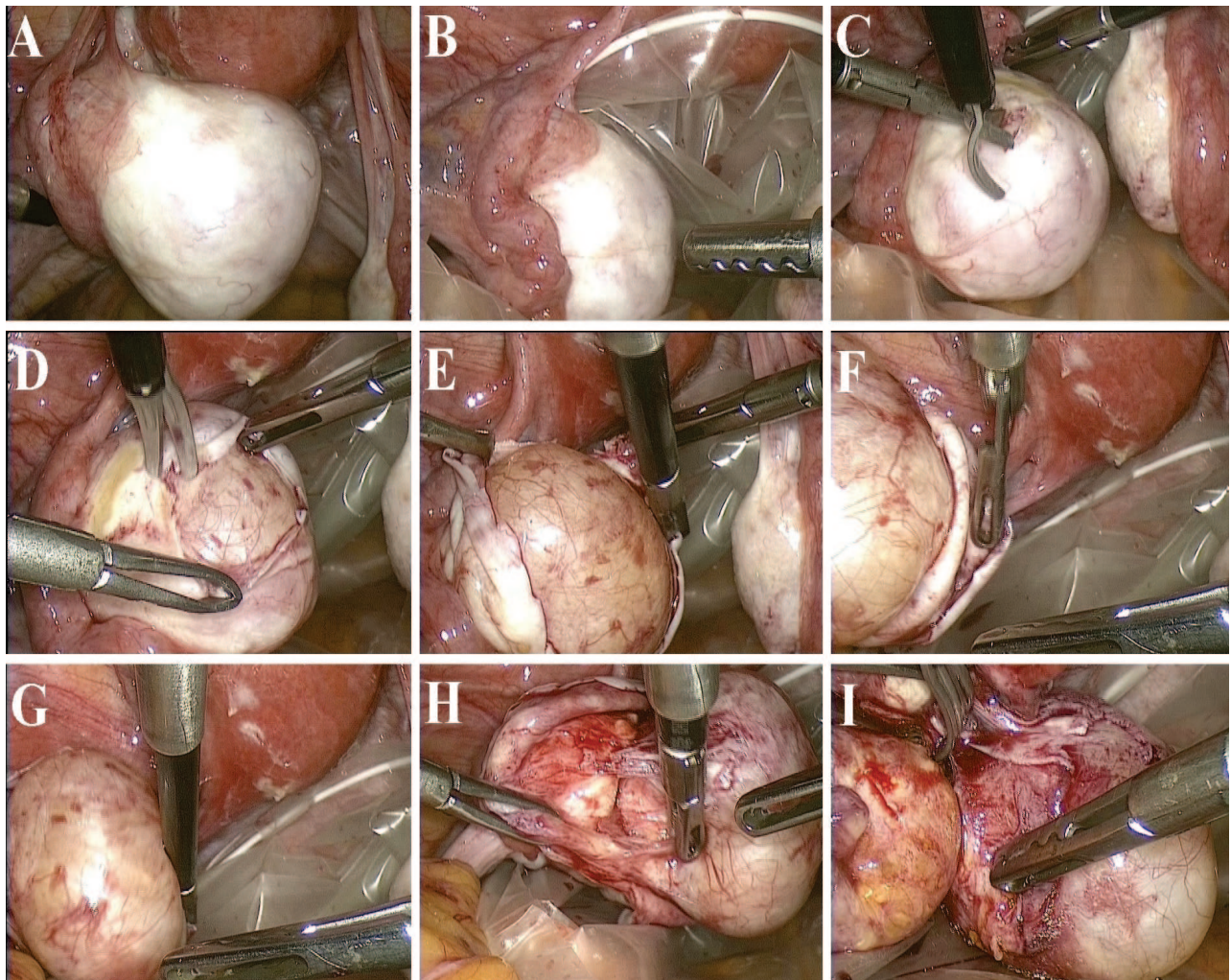
In this case, after the positioning of the endobag, the cyst is punctured using a laparoscopic needle and all its contents are aspirated. As it is predominantly sebaceous content and hair, aspiration is often not easy and occlusion of the suction system occurs. When opting for puncture before the cystectomy the ideal, then, is to have a 10 mm vacuum available.

Then, the cyst is irrigated and washed several times with 0.9% saline or Lactated Ringer's solution, taking care so that there is no leakage of the wash liquid. The separation of the cyst wall from the ovarian parenchyma is performed with the aid of three graspers, using traction and countertraction. (Figure 4)

### Oophorectomy

Normally oophorectomy is not the first therapeutic choice for women with ovarian dermoid cysts, since this disorder is usually identified in young women of reproductive age. We recommend oophorectomy only in those women during perimenopause.

The surgical technique is simple. After placing the endobag inside the abdominal cavity, the ovary is pulled by the assistant, who grasps the utero-ovarian ligament. The anterior layer of the broad ligament is coagulated and sectioned close to the round ligament, followed by coagulation and cutting of the posterior lamina of the broad ligament, toward/ in the direction of the pelvic infundibulum ligament. In this way, the broad ligament is fenestrated, leaving the ureter alongside the pelvic wall,



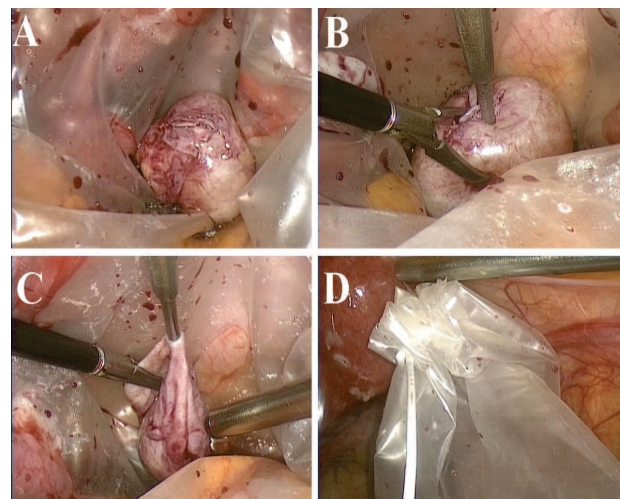
**Figure 2** - (A) Dermoid cyst in left ovary. (B) Positioning of endobag under the ovarian lesion/cyst. (C) Opening of the ovarian parenchyma in the contra-lateral portion of pelvic infundibulum. (D) Enlargement of the opening in the ovarian parenchyma. (E to G) Enucleation of the dermoid cyst. (H and I) Finalizing the cystectomy.

thereby avoiding iatrogenic ureteral injuries. The pelvic infundibulum is then coagulated and cut using bipolar forceps, harmonic bisturi/scalpel, Enseal®, or linear cutting stapler. Finally, the utero-ovarian ligament is coagulated and sectioned. Another approach is, after fenestration of the broad ligament, perform the coagulation of the utero-ovarian ligament and fallopian tube, followed by the coagulation of the pelvic infundibulum (Figure 5).

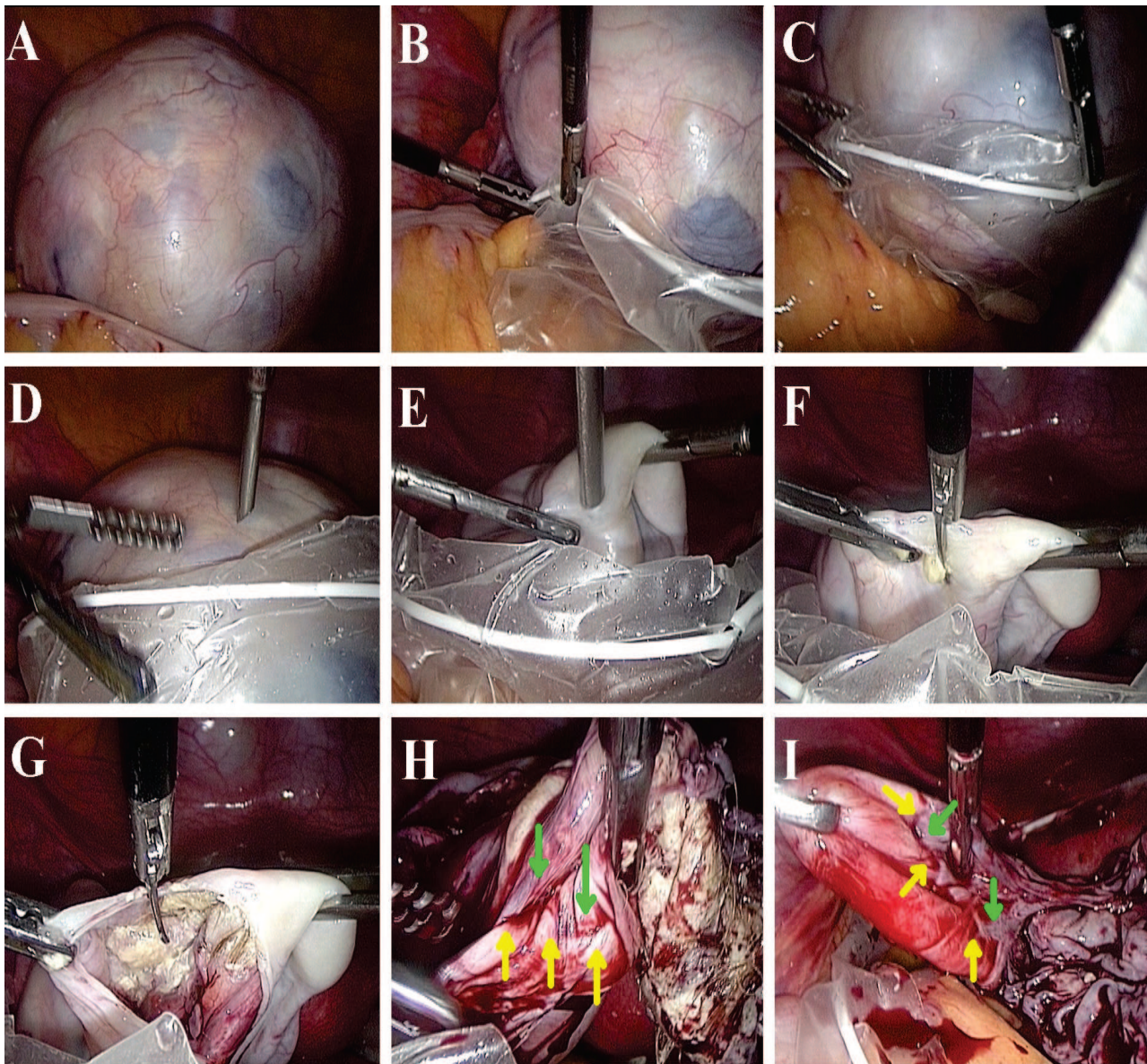
The ovary is punctured inside the endobag and its contents are aspirated.

#### WASHING THE PELVIC CAVITY AND REMOVAL OF THE ENDOBAG

The pelvic cavity is washed with 0.9% saline or Lactated Ringer's solution. In the event of accidental rupture of the cyst with contamination of



**Figure 3** - Puncture of the dermoid cyst – enucleated from the ovarian parenchyma – using a laparoscopic needle, protected by the endobag.



**Figure 4-** (A) Dermoid cyst in left ovary. (B and C) Positioning/Placement of the cyst inside the endobag. (D and E) Puncture of the cyst with a laparoscopic needle. (F and G) Expansion of the orifice/puncture hole with scissors. (H and I) Separation of the cyst wall (green arrows) from the ovarian parenchyma (yellow arrows).

the pelvis with intra-cystic content, copious washing of the pelvic cavity with about 4 liters of solution is recommended to prevent chemical peritonitis.<sup>1</sup>

Hemostasis is reviewed/revised with bipolar forceps/cautery. During this process it is prudent to support the outer surface of the ovary on the uterine wall and perform bipolar coagulation of the inner surface of the ovary (Figure 6).

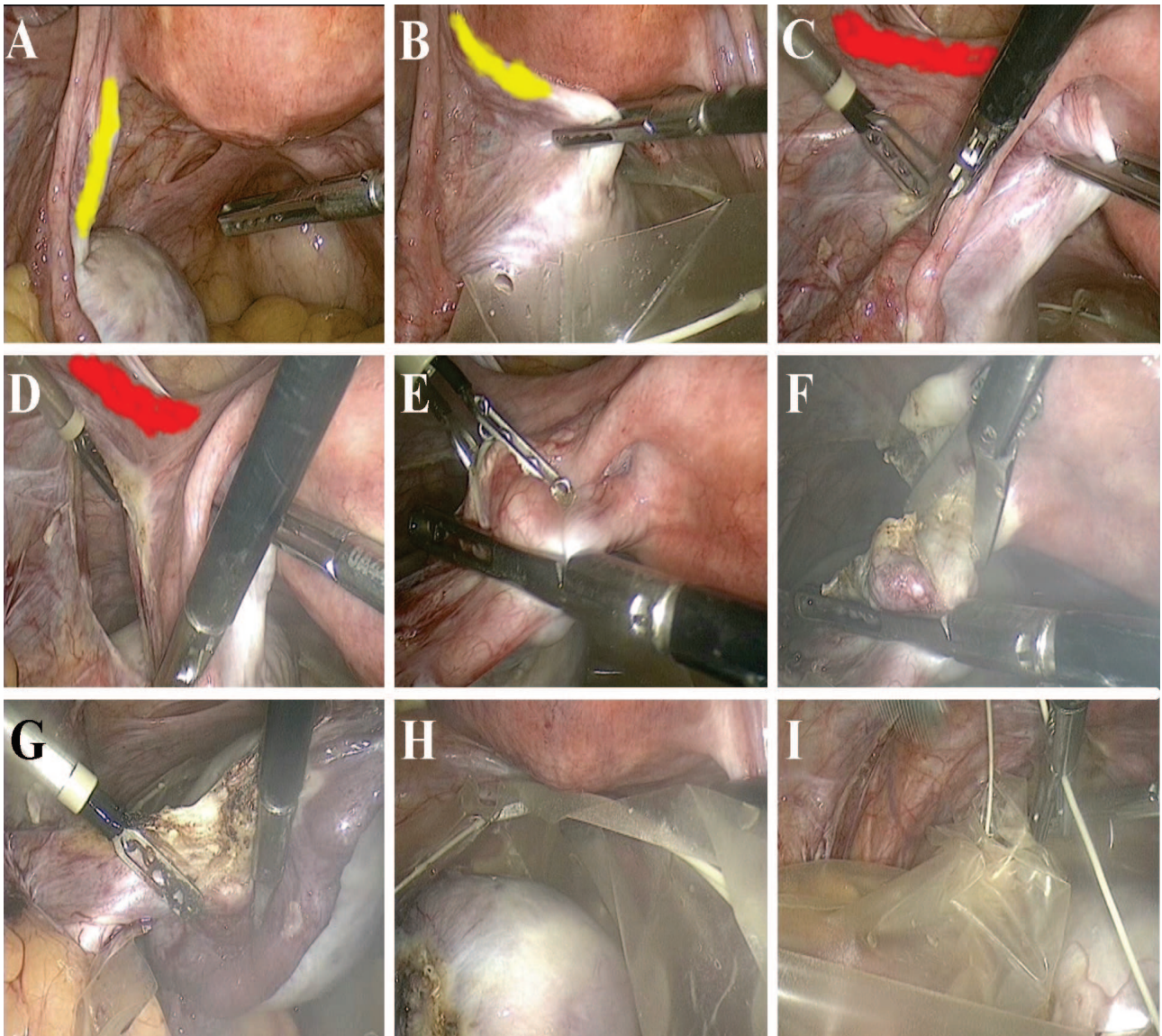
The cyst is removed from the abdominal cavity inside of the endobag through the umbilical incision (Figure 7).

### CLOSING THE APONEUROSIS AND SUTURING THE SKIN

The aponeurosis of the 10mm umbilical puncture is sutured with zero vicryl, and the skin is sutured/closed with inverted sutures using 3-0 Monocryl.

### DISCUSSION

The treatment of benign ovarian cysts by laparoscopy is a reality. The benefits of laparoscopy

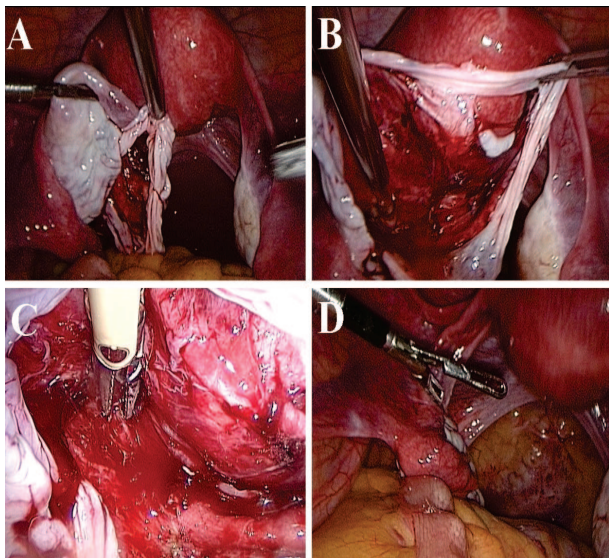


**Figure 5** - (A and B) Mobilization of the left dermoid cyst through the manipulation of the utero-ovarian ligament (yellow). (C and D) Coagulation and cutting of the left broad ligament, fenestrating it from the round ligament (in red) to the pelvic infundibulum. (E and F) Coagulation and cutting of the utero-ovarian ligament and fallopian tube. (G) Coagulation of pelvic infundibulum. (H and I) Dermoid cyst within the endobag ready to be removed from the abdominal cavity.

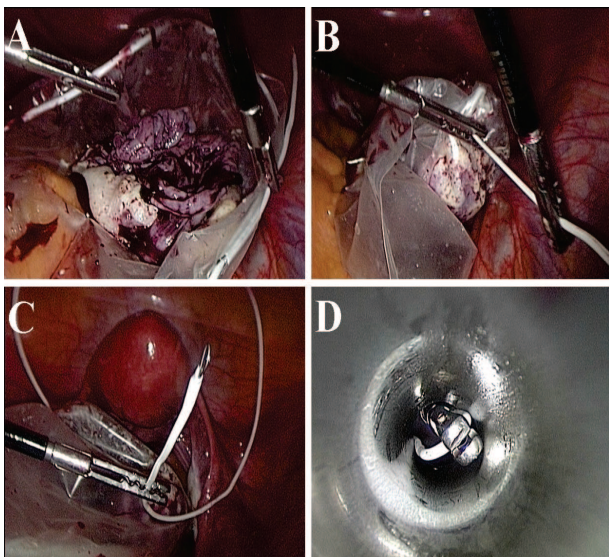
compared to laparotomy are well established in the literature: fewer postoperative complications (including fever and infection), less postoperative pain, shorter hospital stays, and lower total cost.<sup>10</sup> LIN and cols<sup>11</sup> compared cystectomy for dermoid tumors performed by laparoscopy and by laparotomy and found that laparoscopy was associated with a longer operative time, however, the hospital stay was shorter and the postoperative recovery faster. Similar findings were reported by BENEZRA and cols.,<sup>12</sup> who also identified a higher incidence of leakage of intra-cystic contents into the abdominal

cavity with the laparoscopic technique (31.4% vs. 4.1%).

There is a common sense among gynecologic surgeons that extravasation of the contents of the dermoid cyst into the abdominal cavity can lead to complications (such as chemical peritonitis, the spread of infection or peritoneal irritation with subsequent formation of peritoneal adhesions) and this remains the biggest concern of laparoscopic treatment of dermoid cysts. Despite this increased risk of leakage when approaching/addressing the dermoid cyst by



**Figure 6 -** Hemostasis of the ovary and revision/review of the abdominal cavity.



**Figure 7 -** (A and B) Positioning of the cyst inside the endobag and closing the endobag. (C and D) Externalization/Exteriorization of the endobag wire/string through the umbilical port/trocar.

laparoscopy, most authors report that there is no increase in morbidity.<sup>12, 13</sup>

In the series of SHAWKI *et al.*<sup>1</sup>, the leakage occurred in 324 of 496 cases of laparoscopic cystectomy for dermoid tumor (65.3%), but chronic granulomatous peritonitis developed in only one of the 324 patients (0.3%). In the experience of the service of Clermont-Ferrand, the use of the endobag minimized or avoided/prevented contamination of the abdominal cavity in case of accidental rupture of dermoid cysts during laparoscopic cystectomy. The incidence of

chemical peritonitis in this series was 8% (2 cases) when considering only the 26 patients in whom extravasation occurred and was not protected by an endobag.

In this article we present some important technical details to be followed during the laparoscopic approach of dermoid cysts. The use of endobag seems essential because it reduces peritoneal contamination in the event of accidental rupture of the cyst dermóide.<sup>5, 8</sup> In the event of extravasation, copious irrigation of the abdominal cavity with Lactated Ringer's solution or normal saline is indicated, in an attempt to remove even microscopic particles of the cyst content.<sup>1, 9</sup>

With advances in diagnostic methods, especially transvaginal ultrasound, dermoid cysts are being diagnosed while still small. The average diameter of these lesions when diagnosed is 50 to 70mm,<sup>5,14</sup> although they can be much larger. A lesion/cyst of this diameter is easily inserted into and manipulated inside the endobag. Puncture can be done at the beginning of surgery or after removal of the intact cyst. In deciding to perform the puncture at the start of surgery, one should be attentive to the need to irrigate the interior of the cyst in order to remove all of the intracystic content before proceeding to cystectomy.

When you choose not to perform the puncture at the beginning of the surgery one should perform movements delicately to avoid any accidental rupture of the cyst during the cystectomy. For lesions larger than 100mm in diameter, which do not fit inside the endobag, one option is to perform an open laparoscopy.<sup>15</sup> After the skin incision, the ovary is punctured and aspirated under direct vision through the umbilical incision. The puncture site is closed with a purse-string suture using 1vicryl and the ovary is reinserted into the abdomen. The laparoscopic cystectomy is then performed.

The preservation of ovarian function is feasible and effective for women of reproductive age suffering from benign ovarian cysts.<sup>16</sup> TSIKOURAS and cols.<sup>17</sup> observed an overall rate of intra-uterine pregnancy of 83.7% in a group of 43 women treated for ovarian dermoid cyst by laparoscopy, and who desired to become pregnant after surgery. One patient (2.32%) had an ectopic pregnancy.

Some authors<sup>13</sup> believe that the risk of recurrence of the dermoid cyst is greater when the treatment is performed laparoscopically, with a probability of recurrence within 2 years of 7.6% in

patients treated by laparoscopy and 0% in those treated by laparotomy. Probably the experience of the surgeon has a key role in the recurrence rate and the tendency is that, once the surgeon climbs/overcomes the laparoscopy learning curve, recurrence rates will be the same whether the dermoid cyst was treated by laparoscopy or laparotomy.

## FINAL CONSIDERATIONS

The benefits of minimally invasive surgery are unquestionable compared to open surgery. The standardization of surgical technique will ensure that the dermoid cysts are treated by laparoscopy safely and with minimal morbidity.

## RESUMO

A laparoscopia é o padrão ouro para a abordagem de cistos ovarianos benignos. A padronização da técnica cirúrgica e a aplicação de algumas táticas durante o tratamento laparoscópico dos cistos dermóides aumentam a segurança do procedimento e reduzem a morbidade às pacientes. Neste artigo descrevemos os detalhes técnicos da abordagem laparoscópica dos cistos dermóides.

**Palavras chave:** Teratoma cístico benigno, cisto dermóide, laparoscopia, extravasamento.

## REFERENCES

1. Shawki O, Ramadan A, Askalany A, Bahnassi A. Laparoscopic management of ovarian dermoid cysts: potential fear of dermoid spill, myths and facts. *Gynecol Surg* 2007; 4: 255-60.
2. Peterson WF, Prevost EC, Edmunds FT, Hundley JM Jr, Morris FK. Benign cystic teratomas of the ovary; a clinico-statistical study of 1,007 cases with a review of the literature. *Am J Obstet Gynecol* 1955; 70: 368-82.
3. Shawki O, Soliman I, Ebrachy A, El Sadek M, Bahanassy A. Laparoscopic management of ovarian dermoid cysts. *MEFSJ* 2004; 9: 58-65.
4. Richardson G, Robertson DI, O'Connor ME, Nation JG, Stuart GC. Malignant transformation occurring in mature cystic teratomas of the ovary. *Can J Surg* 1990; 33: 499-503.
5. Kondo W, Bourdel N, Cotte B, Tran X, Botchorishvili R, Jardon K, et al. Does prevention of intraperitoneal spillage when removing a dermoid cyst prevent granulomatous peritonitis? *BJOG* 2010; 117: 1027-30.
6. Nezhat C, Winer WK, Nezhat F. Laparoscopic removal of dermoid cysts. *Obstet Gynecol* 1989; 73: 278-81.
7. Chapron C, Dubuisson JB, Samouh N, Foulot H, Aubriot FX, Amsquer Y, et al. Treatment of ovarian dermoid cysts. Place and modalities of operative laparoscopy. *Surg Endosc* 1994; 8: 1092-5.
8. Campo S, Campo V. A modified technique to reduce spillage and operative time: laparoscopic ovarian dermoid cyst enucleation 'in a bag'. *Gynecol Obstet Invest* 2011; 71: 53-8.
9. Kavallaris A, Mytas S, Chalvatzas N, Nikolettos N, Diedrich K, Bohlmann MK, et al. Seven years' experience in laparoscopic dissection of intact ovarian dermoid cysts. *Acta Obstet Gynecol Scand* 2010; 89: 390-2.
10. Medeiros LR, Rosa DD, Bozzetti MC, Fachel JM, Furness S, Garry R, et al. Laparoscopy versus laparotomy for benign ovarian tumour. *Cochrane Database Syst Rev* 2009; 15: CD004751.
11. Lin P, Falcone T, Tulandi T. Excision of ovarian dermoid cyst by laparoscopy and by laparotomy. *Am J Obstet Gynecol* 1995; 173: 769-71.
12. Benezra V, Verma U, Whitted RW. Comparison of laparoscopy versus laparotomy for the surgical treatment of ovarian dermoid cysts. *Gynecol Surg* 2005; 2: 89-92.
13. Laberge PY, Levesque S. Short-term morbidity and long-term recurrence rate of ovarian dermoid cysts treated by laparoscopy versus laparotomy. *J Obstet Gynaecol Can* 2006; 28: 789-93.
14. Stany MP, Hamilton CA. Benign disorders of the ovary. *Obstet Gynecol Clin North Am* 2008; 35: 271-84.
15. Lee LC, Sheu BC, Chou LY, Huang SC, Chang DY, Chang WC. An easy new approach to the laparoscopic treatment of large adnexal cysts. *Minim Invasive Ther Allied Technol* 2010; *in press*.
16. Retto G, Santoro G, Sturlese E, De Dominicis R, Villari D, Retto A, et al. Efficacy of laparoscopic stripping for ovarian cysts: Histological and clinical findings. *J Obstet Gynaecol Res* 2011; *in press*.
17. Tsikouras P, Liberis V, Galazios G, Savidis A, Teichmann AT, Vogiatzaki T, et al. Laparoscopic treatment of ovarian dermoid cysts. *Clin Exp Obstet Gynecol* 2008; 35: 124-9.

### Corresponding Author

DR. WILLIAM KONDO  
Avenida Getulio Vargas 3163 Apt. 21  
Curitiba, PR 80240-041  
Tel: (41) 3259-6655  
E-mail: williamkondo@yahoo.com  
Site: drwilliamkondo.site.med.br